

Cardiac Catheterization

Andrew Ying-Siu Lee, MD, PhD.

Hemodynamic Principles

- **Pressure wave** = complex periodic fluctuation in force per unit area
- **Fundamental frequency** = number of pressure wave cycles (from one systole to another) in 1 second
- **Harmonic** = multiples of fundamental frequency
- **Fourier analysis** = pressure wave represented by summation of a series of simple sine waves of differing amplitude and frequency (= Fourier series)

BLOOD FLOW MEASUREMENT:-

- **cardiac output (CO)** = quantity of blood delivered to systemic circulation per unit time (l/min)
- **determination of cardiac output** =
Fick oxygen method, Indicator
dilution method
eg. thermodilution method

$$\text{CO} = \frac{\text{oxygen consumption } (=2000/\sqrt{\text{age} + 9 \times \text{BSA}})}{(\text{Ao}\% - \text{PA}\%) \times \text{oxygen content } (=1.36 \times \text{Hb})} \times 10$$

VASCULAR RESISTANCE MEASUREMENT:-

- systemic vascular resistance (dynes-sec-cm⁻⁵) =
$$Ao - RA / CO \times 80$$
- pulmonary vascular resistance =
$$PA - LA / CO \times 80$$

SHUNT DETECTION:-

- **left-to-right shunts:** measure oxygen saturation in RV, RA, superior vena cava and inferior vena cava etc. sequentially (=oximetry run). If step-up (>2%) in one of right heart chambers → left-to-right shunt
- **right-to-left shunts:** measure oxygen saturation in PV, LA, LV and aorta sequentially. If step-down in left heart chambers → right-to-left shunt

■ **Systemic blood flow (Q_s) =**

oxygen consumption

$Ao\% - (VSD \text{ or } ASD \text{ sat}\%) \times \text{oxygen content} \times 10$

$VSD \text{ sat}\% = HRA + RA + LRA/3$

$ASD \text{ sat}\% = 3SVC + 1 IVC/4$

■ **Pulmonary blood flow (Q_p) =**

oxygen consumption

$(Ao\% - Pa\%) \times \text{oxygen content} \times 10$

If $Q_p > Q_s \rightarrow$ left-to-right shunt

If $Ao\% < 95\% \rightarrow$ right-to-left shunt

CALCULATION OF VALVE ORIFICE AREA:-

■ **Gorlin formula:**

$$\text{mitral valve area} = \frac{\text{CO/DFP}}{38 \sqrt{\text{PCW} - \text{LV}}}$$

diastolic filling period (DFP) or systolic ejection period (SEP if aortic valve) =

$$\frac{\text{length of diastolic(or systolic if aortic valve) phase (mm) in 5 cycles}}{\text{total length (systole + diastole) in 5 cycles}}$$

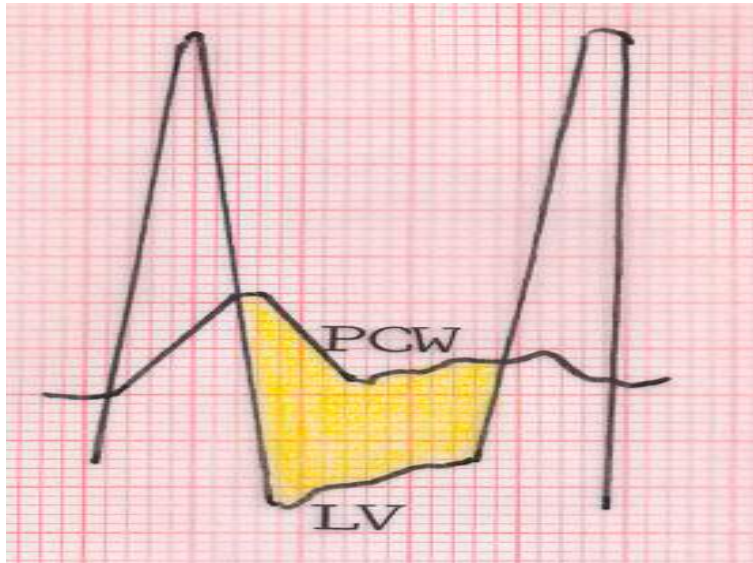
X 60

$$\text{PCW} - \text{LV gradient} = \frac{\text{area of 5 gradients (mm}^2\text{)}}{\text{DFP}}$$

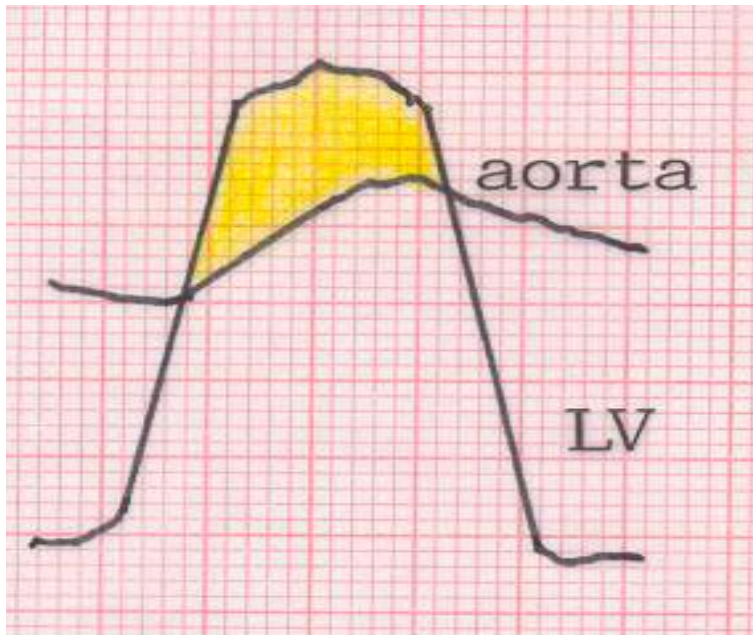Simplified Hakki formula:

$$\text{valve area} = \frac{\text{cardiac output (l/min)}}{\sqrt{\text{pressure gradient}}}$$

LV – PCW gradient:



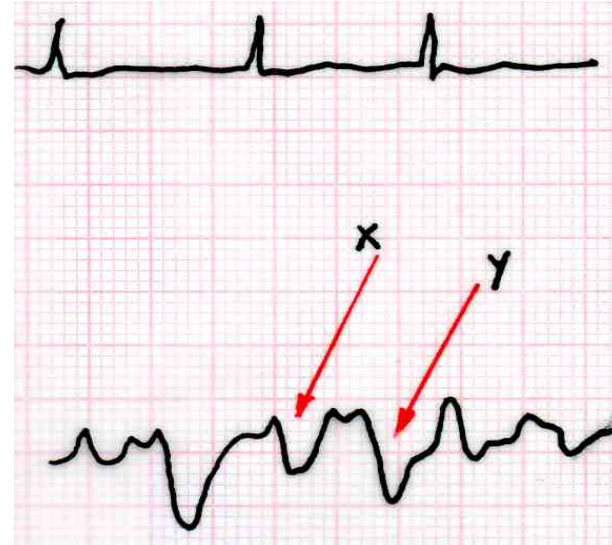
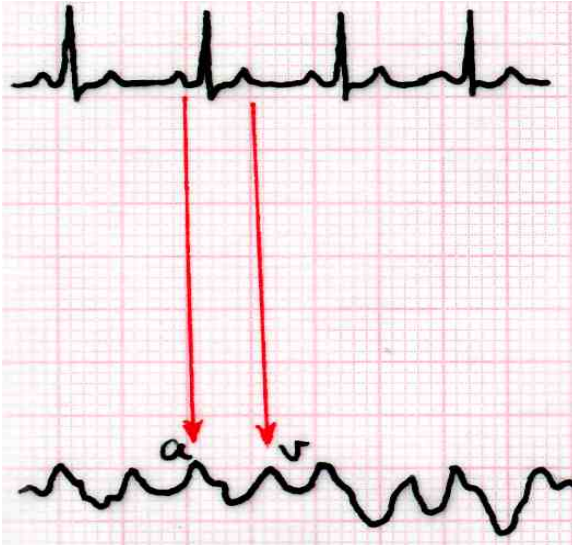
■ LV – aorta gradient:



Normal Waveforms

Right atrial waveform (2-6mmHg):-

- Characterized by a and v waves (normally $a > v$), x and y descents.



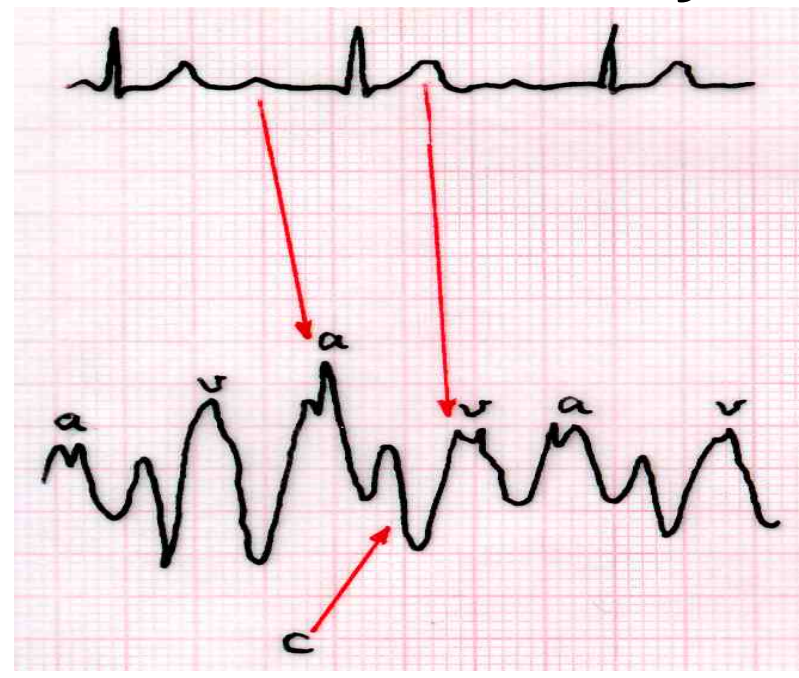
a wave = RA pressure due to atrial contraction (about 80 ms after electrocardiographic P wave)

x descent = pressure drop due to atrial relaxation + atrioventricular downward motion due to ventricular systole

v wave = RA pressure due to passive venous filling at atrial diastole (at same time as ventricular systole)

y descent = pressure drop due to rapid emptying of RA when tricuspid valve open

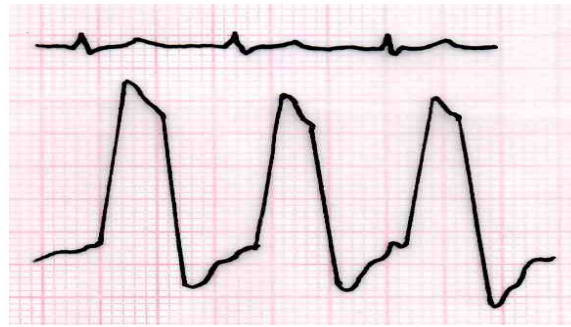- **c wave (sometimes occur) after a wave, due to sudden motion of tricuspid annulus toward right atrium at ventricular systole:**



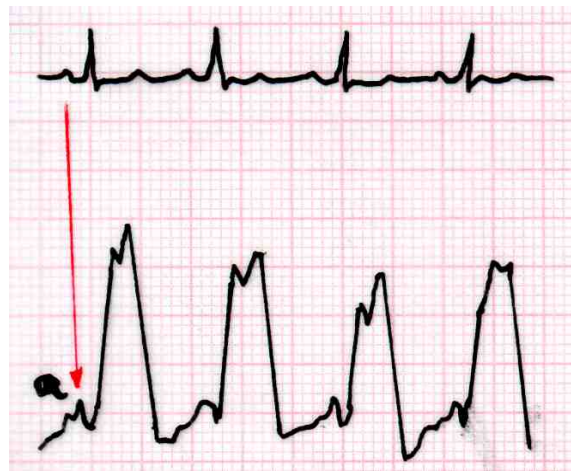Inspiration → x and y descent more prominent, due to decreased intrathoracic pressure increasing the passive right ventricular filling.

Right ventricular waveform (20-30 mmHg):-

- Normal RV systolic pressure = 20-30mmHg; RV end-diastolic pressure = 0-8 mmHg
- Characterized by rapid pressure rise (ventricular contraction) and drop (ventricular relaxation) with gradually diastolic phase

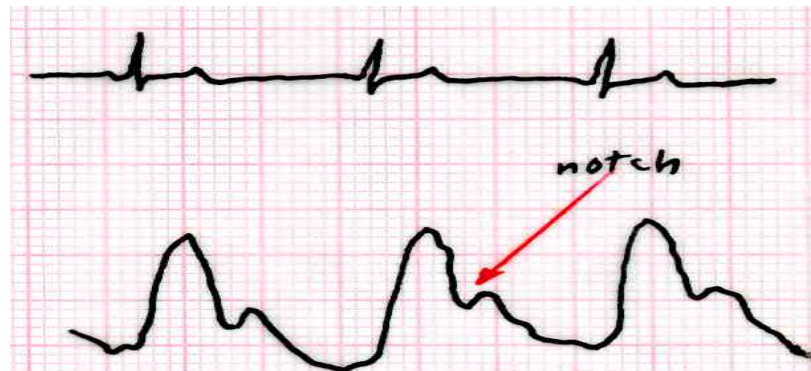


- a wave usually absorbed by compliant right ventricle. If noncompliant (eg pulmonary hypertension, right ventricular hypertrophy, volume overload) → prominent a wave



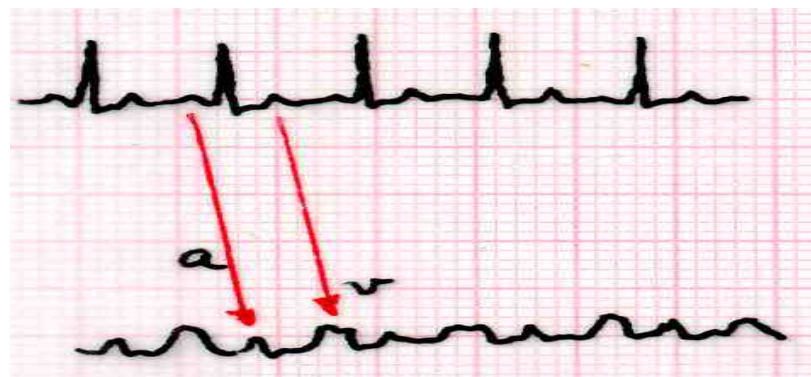
Pulmonary artery waveform:-

- Normal pulmonary artery systolic pressure = 20-30mmHg; diastolic pressure = 4-12 mmHg
- Characterized by rapid pressure rise, systolic peak (within electrocardiographic T wave), pressure decay associated with aortic notch (due to pulmonary valve closure) and diastolic trough



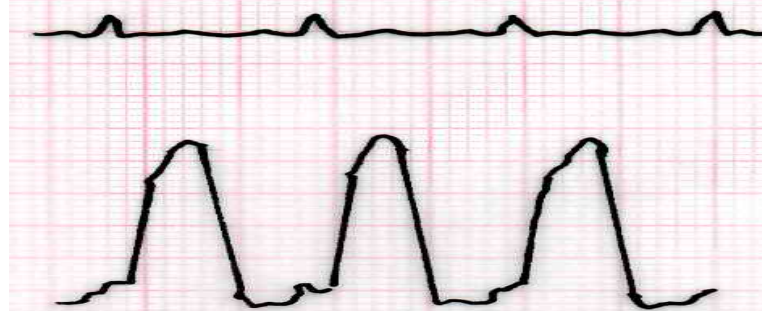
Pulmonary capillary wedge pressure waveform:-

- Normal PCWP = 2-14 mmHg
- = reflection of left atrial pressure, with a and v waves (normally v>a), and x and y descents



Left ventricular waveform:-

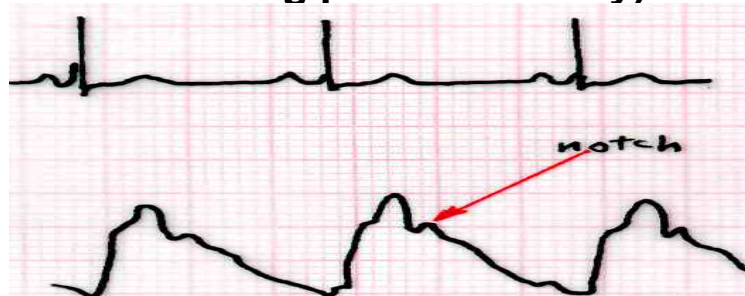
- Normal LV systolic pressure = 90-140mmHg; diastolic pressure = 10-16 mmHg
- Characterized by: very rapid upstroke (ventricular contraction) and decay (ventricular relaxation) with gradually rising diastolic phase



- a wave usually absorbed by compliant left ventricle. If noncompliant → prominent a wave. In heart failure → increased LV end-diastolic pressure (pressure just after the a wave)

Aortic pressure waveform:-

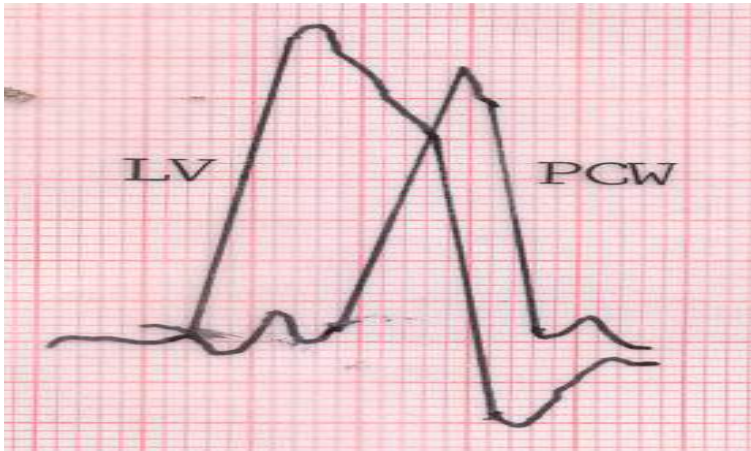
- Normal aortic systolic pressure = 90-140 mmHg; diastolic pressure = 60-90mmHg
- Characterized by: rapid upstroke, a systolic peak, dicrotic notch (due to closure of aortic valve during pressure decay)



Profiles in valvular heart disease

Mitral Stenosis (MS):-

- right and left heart catheterization → measure LV diastolic pressure, LA (or pulmonary wedge) diastolic pressure, heart rate, diastolic filling period, cardiac output → calculate mitral valve orifice area
- LA or PCWP: 1. Prominent a wave (due to residual volume of atrium at onset of atrial systole); 2. Prominent v wave (due to high LA volume and pressure during passive atrial filling); 3. Y descent delayed (due to impaired LA emptying)
- giant v wave in LA or PA pressure tracings

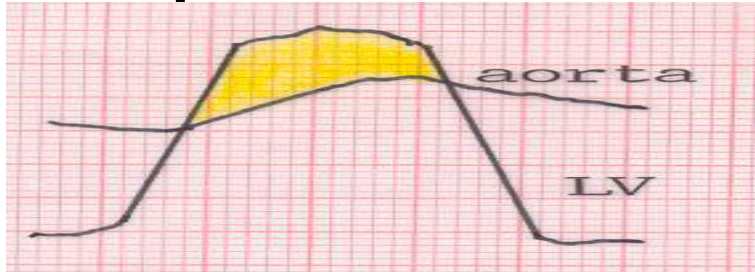


Mitral regurgitation (MR):-

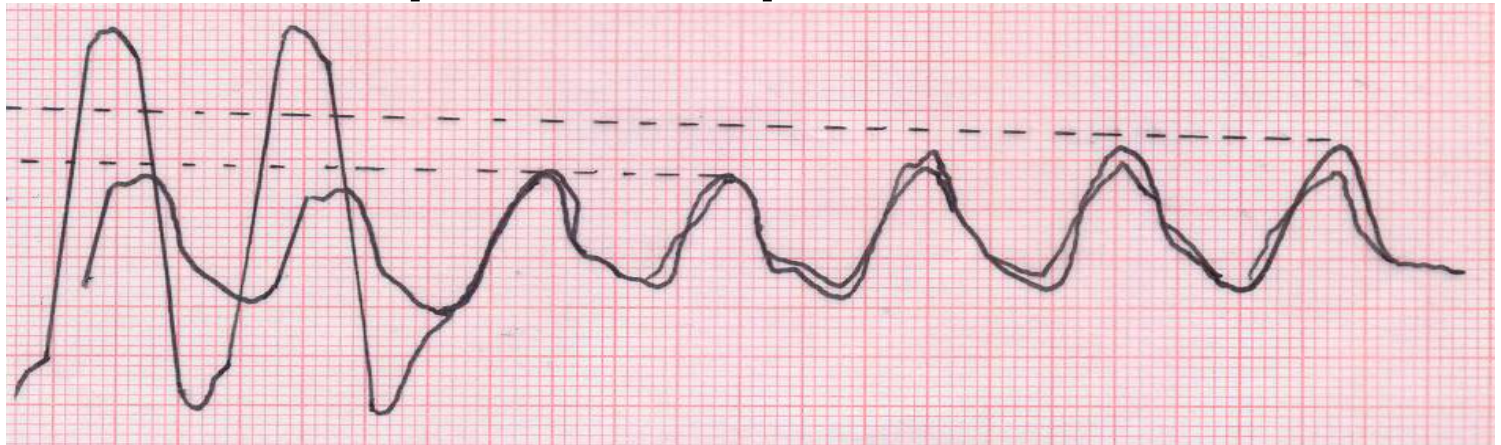- measure CO, right and left heart pressures
- left ventriculograph to evaluate MR

Aortic Stenosis (AS):-

- **LV-Ao pressures recorded simultaneously:**



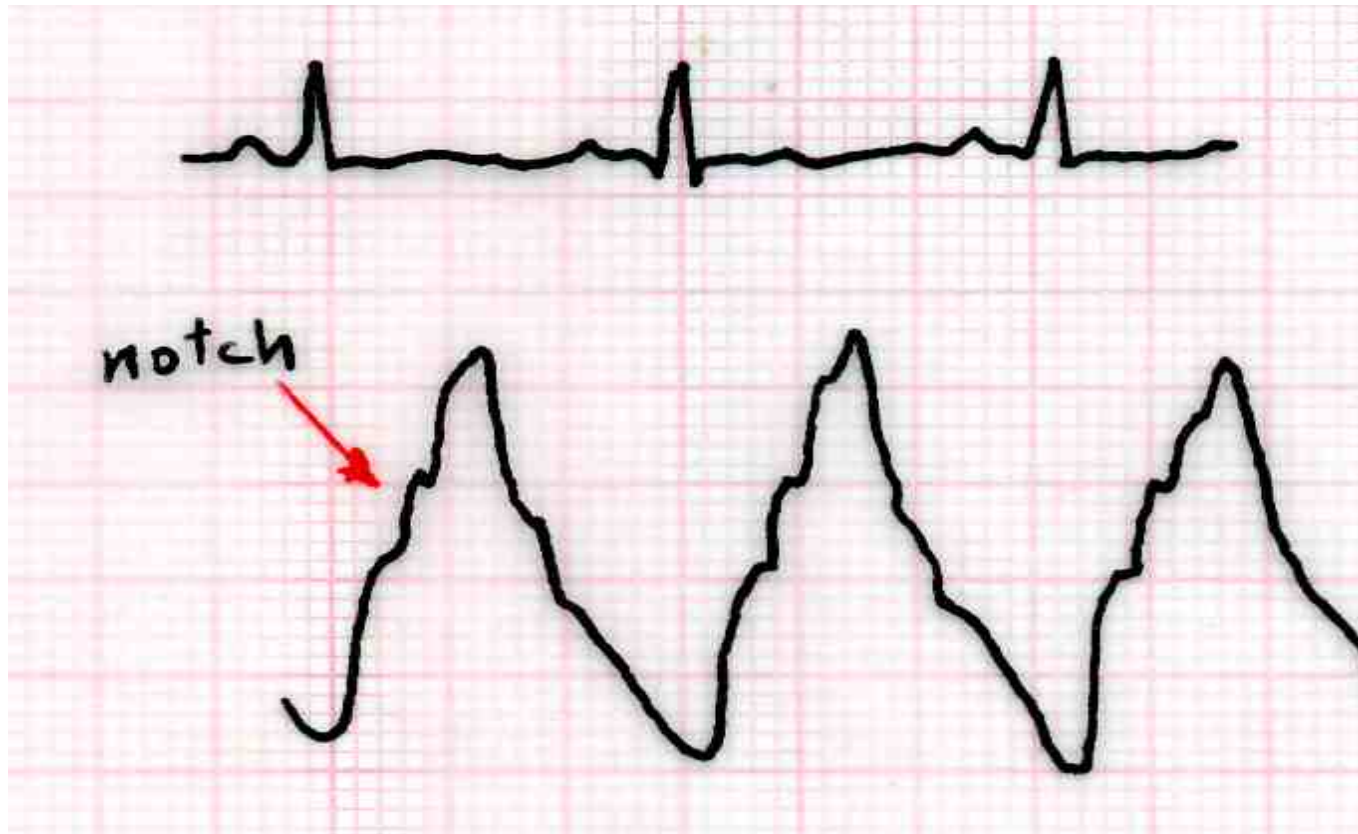- **Carabello sign = rise in arterial pressure during left heart catheter pullback in patients with severe AS**



- **right heart catheterization to measure right heart pressures and CO**
- **left heart catheterization to measure LVEDP, Ao pressure gradient and aortic valve area**

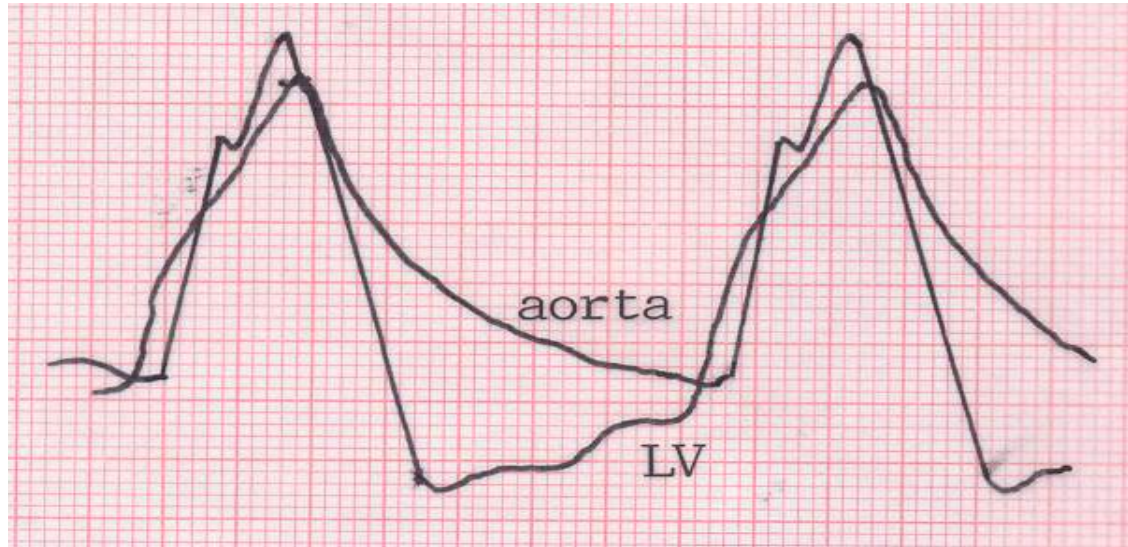Aortic Regurgitation :-

- **Aortic pressure waveform characterized by: wide pulse pressure (= high systolic, low diastolic pressures), anacrotic notch (or shoulder)**



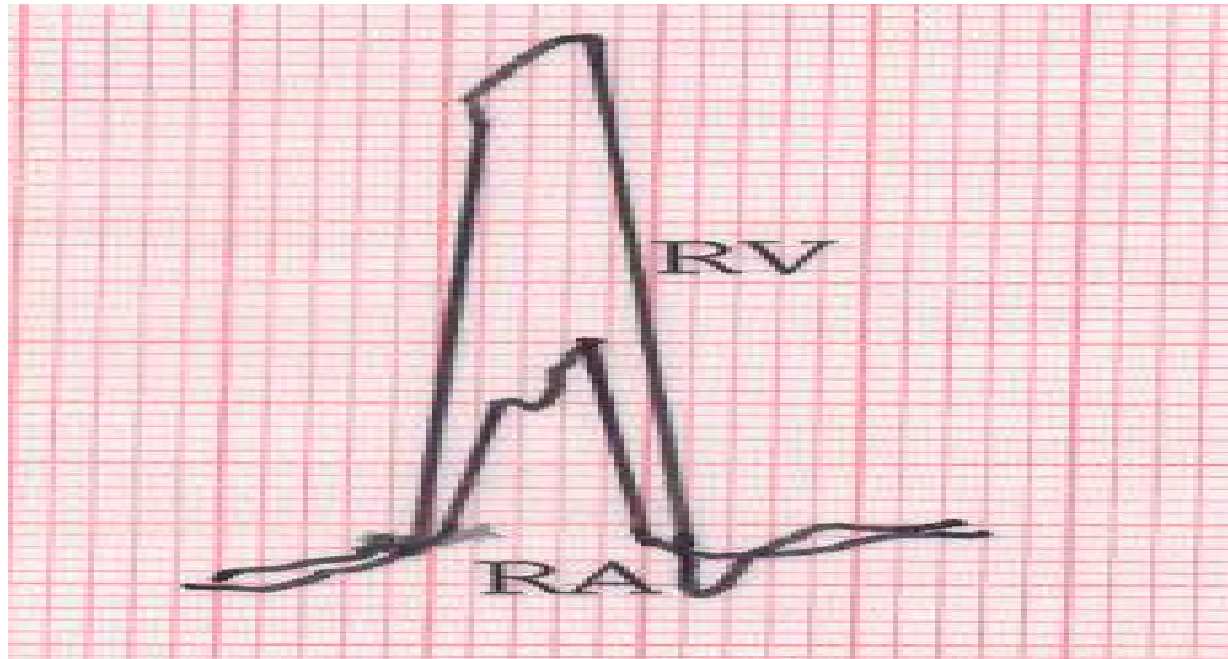
- **Systolic pressure in femoral artery > aortic pressure**

- **LV and Ao pressure tracings: LV and Ao pressures equalize in late diastole (=diastasis)**



- **Aortography to assess severity of AR:**
 - mild AR (1+) = small contrast enter LV in diastole
 - moderate AR(2+)= faint opacification of entire LV
 - moderately severe(3+)= LV well opacified and equal density with aorta
 - severe (4+) = complete and dense opacification (> aorta) in one beat
- Right heart catheterization to measure right heart pressures and CO
- left heart catheterization to measure LVEDP–Ao

■ **Tricuspid Regurgitation (TR):** RA waveform resembling RV pressure



Prominent c-v wave, augmented x and y descents

■ **Tricuspid Stenosis (TS):** simultaneous measurement of RA and RV pressures and valve area

high right atrial pressure, prominent a wave

RA and RV gradient

Profiles in congenital heart disease

ATRIAL SEPTAL DEFECT (ASD):-

- catheter passage through ASD
- oximetry = step up in RA (left-to-right shunt)
- equalization of right and left atrial pressures
- increased RA pressure (due to RV pressure and volume overload) and prominent v wave (due to tricuspid regurgitation from dilated RV)

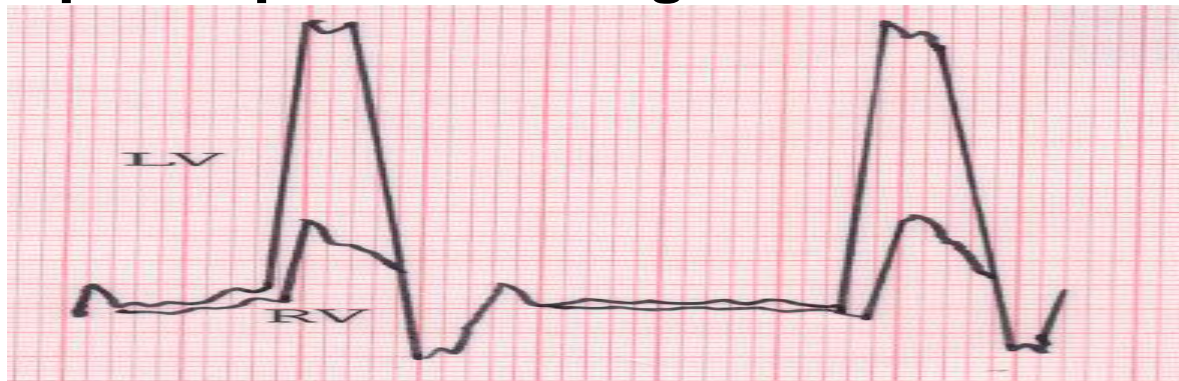VENTRICULAR SEPTAL DEFECT (VSD):-

- catheter passage through VSD
- oximetry = step up in RV
- equalization of right and left ventricular pressures

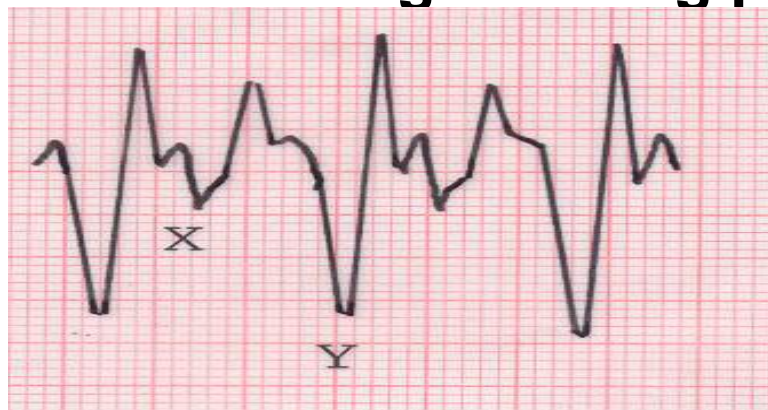Other pressure tracings

1. CONSTRUCTIVE PERICARDITIS:-

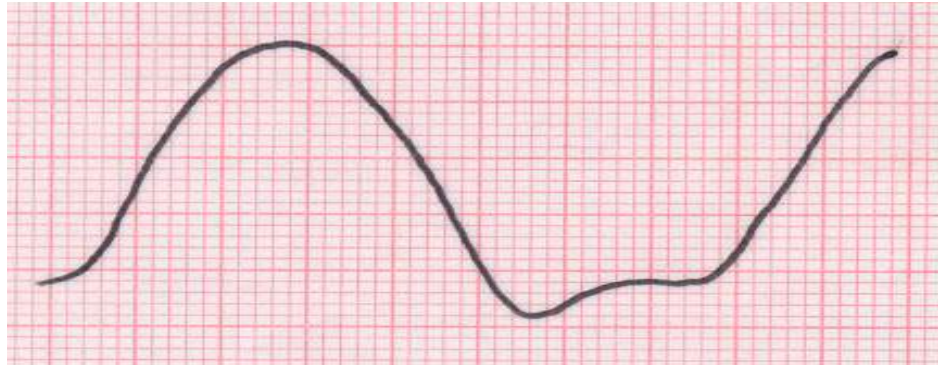
- equilibration of left and right ventricular diastolic pressure (within 5 mmHg or less) and dip-and-plateau configuration:



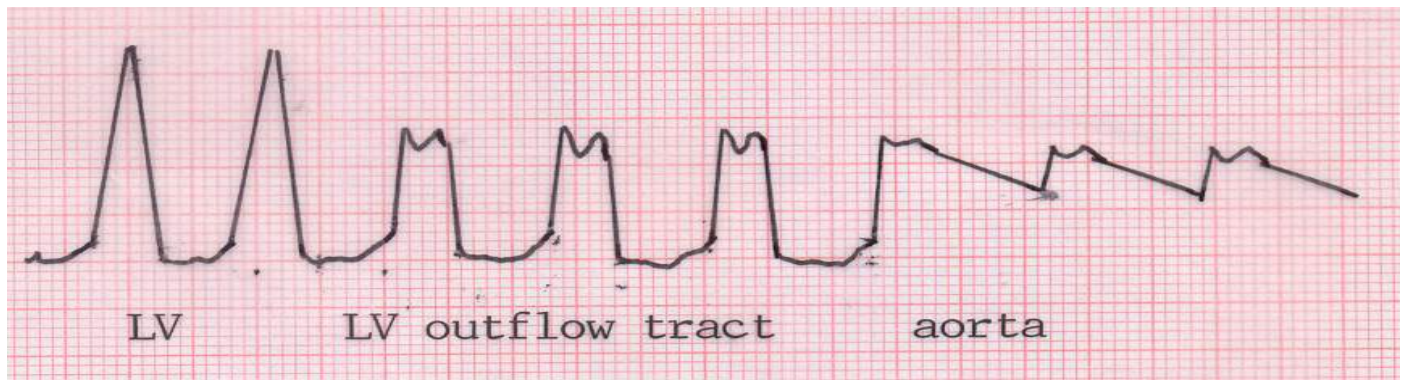
- right atrial pressure tracing showing prominent y descent:



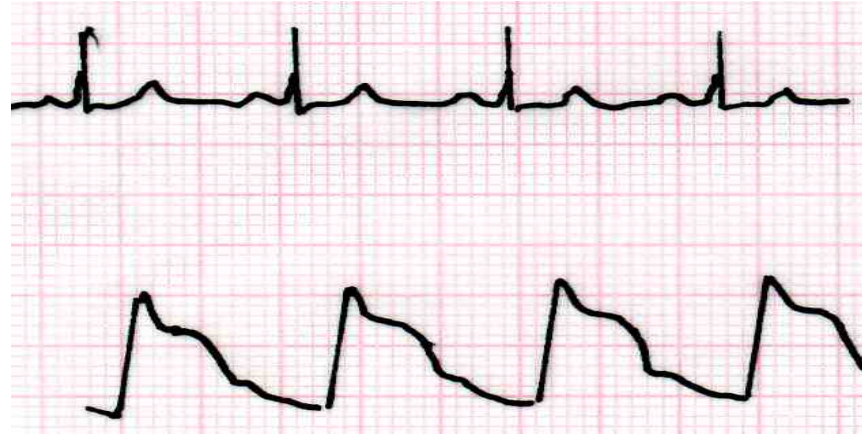- **DILATED CARDIOMYOPATHY:** slowing of left ventricular pressure upstroke and downstroke → triangular appearance and elevated left ventricular diastolic pressure



- **HYPERTROPHIC CARDIOMYOPATHY:** left ventricular catheter pullback showing pressure gradient between left ventricular chamber and outflow tract



- Prominent a wave (→ noncompliant LV)
- “Spike and doom” configuration of aortic waveform



- **RESTRICTIVE CARDIOMYOPATHY:** dip-and-plateau configuration with diastolic pressure in left ventricle higher than right ventricle

